

# GRAY'S

# Anatomy for Students

**Second Edition**


Richard L. Drake

Wayne Vogl


Adam W. M. Mitchell

# MASTER anatomy your way.


These *Gray's Anatomy* resources work together to promote a **vivid, visual understanding** that will carry you through your dissection labs, course exams, and beyond!




Drake, Vogl & Mitchell  
**Gray's Anatomy for Students, 2nd Edition**  
2010. 1150 pp. 1610 ill. Soft-cover book with Student Consult online access. ISBN: 978-0-443-06952-9



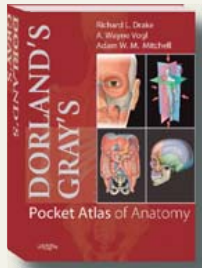
Drake, Vogl, Mitchell, Tibbitts & Richardson  
**Gray's Atlas of Anatomy**  
2008. 576 pp. 1,400 ill. Soft-cover book plus full-text online access. ISBN: 978-0-443-06721-1.



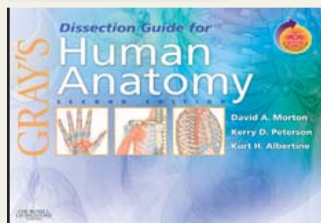
Drake & Vogl  
**Gray's Anatomy for Students Flash Cards**  
2005. 324 flash cards with **Student Consult** online access. ISBN: 978-0-443-06910-9.




Loukas & Carmichael  
**Gray's Anatomy Review**  
Jan. 2009. Soft cover. ISBN: 978-0-443-06938-3.



Drake, Vogl & Mitchell  
**Dorland's/Gray's Pocket Atlas of Anatomy**  
2008. 608 pp. 800 ill. Soft cover. ISBN: 978-0-443-06761-7.




Morton, Peterson & Albertine  
**Gray's Dissection Guide for Human Anatomy, 2nd Edition**  
2007. 568 pp. 400 ill. Soft-cover manual with Student Consult online access. ISBN: 978-0-443-06951-2.



Drake & Lowrie  
**Case-Directed Anatomy Online to Accompany Gray's Anatomy for Students**  
2009. Online.  
For more information or to purchase, visit [evolve.elsevier.com](http://evolve.elsevier.com)

Celebrating 150 years as the  
ultimate word in anatomical certainty



Standing  
**Gray's Anatomy: The Anatomical Basis of Clinical Practice, 40th Edition**  
Expert Consult • Online and Print  
2009. 1,700 pp. 1,200 ill. Print and Online Access. ISBN: 978-0-443-06684-9.

Get the edge you need for an optimal mastery of anatomy.

Pick up your copies today!

This page intentionally left blank

GRAY'S

# Anatomy for Students

SECOND EDITION

**Richard L. Drake, PhD**

Director of Anatomy  
Professor of Surgery  
Cleveland Clinic Lerner College of Medicine  
Case Western Reserve University  
Cleveland, Ohio  
United States of America

**A. Wayne Vogl, PhD**

Professor of Anatomy & Cell Biology  
Department of Cellular and Physiological Sciences  
Faculty of Medicine  
University of British Columbia  
Vancouver, British Columbia  
Canada

**Adam W. M. Mitchell, MBBS, FRCS, FRCR**

Joint Head of Graduate Entry Anatomy  
Imperial College  
University of London  
Consultant Radiologist  
Department of Imaging  
Charing Cross Hospital  
London  
United Kingdom

*Illustrations by*

**Richard Tibbitts** and **Paul Richardson**

*Photographs by*


**Ansell Horn**

GRAY'S

# Anatomy for Students

SECOND EDITION

**Richard L. Drake**  
**A. Wayne Vogl**  
**Adam W. M. Mitchell**



CHURCHILL  
LIVINGSTONE  
ELSEVIER

1600 John F. Kennedy Blvd.  
Ste 1800  
Philadelphia, PA 19103-2899

GRAY'S ANATOMY FOR STUDENTS

Second Edition Domestic Edition with Student Consult Online Access:  
International Edition with Student Consult Online Access:

ISBN: 978-0-443-06952-9

ISBN: 978-0-8089-2406-7

**Copyright © 2010, 2005 by Churchill Livingstone, an imprint of Elsevier Inc.**

**All rights reserved.** No part of this publication may be reproduced or transmitted in any form or by any means, electronic or mechanical, including photocopying, recording, or any information storage and retrieval system, without permission in writing from the publisher. Permissions may be sought directly from Elsevier's Rights Department: phone: (+1) 215 239 3804 (US) or (+44) 1865 843830 (UK); fax: (+44) 1865 853333; e-mail: [healthpermissions@elsevier.com](mailto:healthpermissions@elsevier.com). You may also complete your request on-line via the Elsevier website at <http://www.elsevier.com/permissions>.

#### Notice

Knowledge and best practice in this field are constantly changing. As new research and experience broaden our knowledge, changes in practice, treatment, and drug therapy may become necessary or appropriate. Readers are advised to check the most current information provided (i) on procedures featured or (ii) by the manufacturer of each product to be administered, to verify the recommended dose or formula, the method and duration of administration, and contraindications. It is the responsibility of the practitioner, relying on their own experience and knowledge of the patient, to make diagnoses, to determine dosages and the best treatment for each individual patient, and to take all appropriate safety precautions. To the fullest extent of the law, neither the Publisher nor the Authors assumes any liability for any injury and/or damage to persons or property arising out of or related to any use of the material contained in this book.

The Publisher

#### Library of Congress Cataloging-in-Publication Data

Drake, Richard L., Ph.D.

Gray's anatomy for students / Richard L. Drake, A. Wayne Vogl, and Adam W. M. Mitchell;  
illustrations by Richard M. Tibbitts and Paul E. Richardson; photographs by Ansell Horn.—2nd ed.

p. ; cm.

Includes index.

ISBN 978-0-443-06952-9

1. Human anatomy. I. Vogl, Wayne. II. Mitchell, Adam W. M. III. Gray, Henry, 1825–1861.  
Gray's anatomy. IV. Title.

[DNLM: 1. Anatomy. QS 4 D762g 2010]

QM23.2.D73 2010

612—dc22

2008046822

*Executive Editor:* William Schmitt

*Managing Editor:* Rebecca Gruliow

*Publishing Services Manager:* Linda Van Pelt

*Project Manager:* Frank Morales

*Design Direction:* Lou Forgione

*Marketing Manager:* Allan McKeown

Printed in Canada

Last digit is the print number: 9 8 7 6 5 4 3 2

Working together to grow  
libraries in developing countries

[www.elsevier.com](http://www.elsevier.com) | [www.bookaid.org](http://www.bookaid.org) | [www.sabre.org](http://www.sabre.org)

ELSEVIER

BOOK AID  
International

Sabre Foundation

# Editorial review board

**Anthony M. Adinolfi, PhD**

Adjunct Professor Emeritus, Department  
of Pathology and Laboratory Medicine  
UCLA School of Medicine  
Los Angeles, California, USA

**Kurt H. Albertine, PhD**

Professor of Pediatrics  
Medicine (Adjunct), Neurobiology and  
Anatomy (Adjunct)  
The University of Utah School of Medicine  
Salt Lake City, Utah, USA

**Gail Amort-Larson, MScOT**

Associate Professor, Department of  
Occupational Therapy  
Faculty of Rehabilitation Medicine  
University of Alberta  
Edmonton, Alberta, Canada

**Judith E. Anderson, PhD**

Professor, Department of Human  
Anatomy and Cell Sciences  
Faculty of Medicine, University of  
Manitoba  
Winnipeg, Manitoba, Canada

**S. P. Banumathy, MS, PhD**

Director and Professor, Institute of  
Anatomy  
Madurai Medical College  
Madurai, India

**David H. Bechhofer, PhD**

Professor, Department of Pharmacology  
and Biological Chemistry  
Mount Sinai School of Medicine  
New York, New York, USA

**N. Barry Berg, PhD**

Assistant Dean  
Director, Gross Anatomy  
Department of Cell and Developmental  
Biology  
SUNY Upstate Medical University  
Syracuse, New York, USA

**Raymond L. Bernor, PhD**

Professor, Department of Anatomy  
Howard University College of Medicine  
Washington, DC, USA

**Edward T. Bersu, PhD**

Professor of Anatomy  
Department of Anatomy  
University of Wisconsin Medical School  
Madison, Wisconsin, USA

**Homero Felipe Bianchi, MD**

Third Chair, Department of Normal  
Human Anatomy  
Faculty of Medicine  
University of Buenos Aires  
Buenos Aires, Argentina

**David L. Bolender, PhD**

Associate Professor, Department of Cell  
Biology, Neurobiology and Anatomy  
Medical College of Wisconsin  
Milwaukee, Wisconsin, USA

**Walter R. Buck, PhD**

Professor and Chair  
Department of Structural Medicine  
Rocky Vista University  
College of Osteopathic Medicine  
Centennial, Colorado, USA

**Stephen W. Carmichael, PhD, DSc**

Professor and Chair Emeritus, Department  
of Anatomy  
Mayo Clinic College of Medicine  
Rochester, Minnesota, USA

**Wayne Carver, PhD**

Associate Professor, Department of  
Cell and Developmental Biology and  
Anatomy  
University of South Carolina School of  
Medicine  
Columbia, South Carolina, USA

**John Chemnitz, MD**

Associate Professor, Department of  
Anatomy and Neurobiology  
Southern University of Denmark  
Odense, Denmark

**Shih-Chieh Chen, PhD**

Associate Professor, Department of  
Anatomy  
Kaohsiung Medical University  
Kaohsiung, Taiwan

**Sou-De Cheng, PhD**

Associate Professor and Chairman,  
Department of Anatomy  
College of Medicine  
Chang Gung University  
T'ao-yüan, Taiwan

**Hee-Jung Cho, MD, PhD**

Professor, Department of Anatomy  
School of Medicine  
Kyungpook National University  
Daegu, Korea

**Patricia Collins, BSc, PhD**

Associate Professor  
Licensed Teacher of Anatomy  
Anglo-European College of Chiropractic  
Bournemouth, UK

**Maria H. Czuzak, PhD**

Academic Specialist—Anatomical  
Instructor  
Department of Cell Biology and Anatomy  
University of Arizona  
Tucson, Arizona, USA

**P. H. Dangerfield, MD, ILTM**

Senior Lecturer, Department of Human  
Anatomy and Cell Biology  
University of Liverpool  
Liverpool, UK

**Jan Drukker, MD, PhD**

Emeritus Professor of Anatomy and  
Embryology  
Department of Anatomy and Embryology  
Faculty of Medicine  
University of Maastricht  
Maastricht, The Netherlands

**Julian J. Dwornik, BA, MSc, PhD**

Professor of Anatomy, Department of  
Anatomy  
University of South Florida College of  
Medicine  
Tampa, Florida, USA

**John Fitzsimmons, MD**

Assistant Professor, Radiology  
Division of Anatomy  
Michigan State University  
East Lansing, Michigan, USA

# Editorial review board

**Robert T. Gemmell**

Associate Professor, Department of  
Anatomy and Developmental Biology  
The University of Queensland  
St. Lucia, Queensland, Australia

**Gene F. Giggelman, DVM**

Dean of Academics  
Parker College of Chiropractic  
Dallas, Texas, USA

**Adriana C. Gittenberger-de Groot, PhD**

Professor, Head of Department  
Department of Anatomy and Embryology  
Leiden University Medical Center  
Leiden, The Netherlands

**P. Gopalakrishnakone, MBBS, PhD,  
FAMS, DSc**

Professor, Department of Anatomy  
Faculty of Medicine  
National University of Singapore  
Singapore

**J. R. T. Greene, BSc, MBBS, PhD**

Senior Lecturer, Department of Anatomy  
University of Bristol  
Bristol, UK

**Santos Guzmán Lopez, PhD**

Chair, Department of Anatomy  
Faculty of Medicine  
Autonomous University of Nueva León  
Monterrey, Mexico

**Duane E. Haines, PhD**

Professor and Chairman  
Professor of Neurosurgery  
Department of Anatomy  
The University of Mississippi Medical  
Center  
Jackson, Mississippi, USA

**Jostein Halgunset, MD**

Assistant Professor of Anatomy,  
Department of Laboratory Medicine,  
Children's and Women's Health  
Faculty of Medicine  
Norwegian University of Science and  
Technology  
Trondheim, Norway

**Benedikt Hallgrímsson, PhD**

Associate Professor, Department of Cell  
Biology and Anatomy  
University of Calgary  
Calgary, Alberta, Canada

**Jerimiah C. Healy, MA, MBBChir, MRCP,  
PFCR**

Department of Radiology  
Chelsea and Westminster Hospital  
Imperial College School of Medicine  
London, UK

**Heikki J. Helminen, MD, PhD**

Professor and Chairman  
Department of Anatomy  
University of Kuopio  
Kuopio, Finland

**Louis Hermo, BA, MSc, PhD**

Professor, Department of Anatomy and  
Cell Biology  
McGill University  
Montreal, Quebec, Canada

**Maxwell T. Hincke, PhD(Alberta)**

Professor and Director, Anatomy Program  
Department of Cellular and Molecular  
Medicine  
Faculty of Medicine, University of Ottawa  
Ottawa, Ontario, Canada

**J. C. Holstege, MD, PhD**

Associate Professor, Department of  
Neuroscience  
Erasmus Medical Center  
Rotterdam, The Netherlands

**Richard F. Hoyt, Jr, PhD**

Associate Professor, Department of  
Anatomy and Neurobiology  
Boston University School of Medicine  
Boston, Massachusetts, USA

**Alan W. Hryciyshyn, MS, PhD**

Professor, Division of Clinical Anatomy  
The University of Western Ontario  
London, Ontario, Canada

**Sezgin Ilgi, PhD**

Professor, Department of Anatomy  
Faculty of Medicine, Hacettepe University  
Ankara, Turkey

**Kanak Iyer, MBBS, MS**

Professor, Department of Anatomy  
K.J. Somaiya Medical College  
Mumbai, India

**S. Behnamedin Jameie, MSc, PhD**

Assistant Professor, Department of  
Anatomy and Cellular and Molecular  
Research Center  
School of Medicine, Basic Science Center  
Tehran, Iran

**Elizabeth O. Johnson, PhD**

Assistant Professor, Department of  
Anatomy, Histology and Embryology  
University of Ioannina  
Ioannina, Greece

**Panagiotis Kanavaros, MD, PhD**

Department of Anatomy, Histology and  
Embryology  
University of Ioannina  
Ioannina, Greece

**Lars Kayser, MD, PhD**

Associate Professor, Department of  
Medical Anatomy  
University of Copenhagen  
Copenhagen, Denmark

**Jeffrey Kerr, PhD**

Associate Professor, Department of  
Anatomy and Cell Biology  
Faculty of Medicine, Nursing and Health  
Sciences, Monash University  
Melbourne, Victoria, Australia

**Lars Klimaschewski, MD, PhD**

Professor, Department of Neuroanatomy  
Medical University of Innsbruck  
Innsbruck, Austria

**Natsis Konstantinos, MD, PhD, BSc**

Assistant Professor, Department of  
Anatomy  
Medical School, Aristotle University of  
Thessaloniki  
Thessaloniki, Greece

**Rachel Koshi, MBBS, MS, PhD**

Professor of Anatomy  
Department of Anatomy  
Christian Medical College  
Vellore, India

**Subramaniam Krishnan**

Professor of Anatomy  
Head of Department of Anatomy  
University of Malaya  
Kuala Lumpur, Malaysia

**Jeffrey T. Laitman, PhD**

Distinguished Professor of the Mount Sinai  
School of Medicine  
Professor and Director of Anatomy and  
Functional Morphology  
Professor of Otolaryngology  
Center for Anatomy and Functional  
Morphology  
Mount Sinai School of Medicine  
New York, New York, USA

**Alfonso Llamas, MD, PhD**

Professor of Anatomy and Embryology  
Department of Anatomy  
Medical School, Universidad Autónoma  
de Madrid  
Madrid, Spain

**Grahame J. Louw, DVSc**

Professor, Department of Human Biology  
Faculty of Health Sciences  
University of Cape Town  
Cape Town, South Africa

**P.W. Lucas, BSc, PhD**

Professor, Department of Anatomy  
University of Hong Kong  
Hong Kong, China

**Liliana D. Macchi**

Second Chair, Department of Normal  
Human Anatomy  
Faculty of Medicine, University of Buenos  
Aires  
Buenos Aires, Argentina

**Henk van Mameren, MD, PhD**

Professor, Department of Anatomy and  
Embryology  
Faculty of Medicine  
University of Maastricht  
Maastricht, The Netherlands

**Francisco Martinez Sandoval**

Director, Institute of Biological Sciences  
Universidad Autónoma de Guadalajara  
Guadalajara, Mexico

**Robert S. McCuskey, PhD**

Professor and Head, Department of Cell  
Biology and Anatomy  
University of Arizona College of Medicine  
Tucson, Arizona, USA

**Martha D. McDaniel, MD**

Professor of Anatomy, Surgery and  
Community and Family Medicine  
Chair, Department of Anatomy  
Dartmouth Medical School  
Hanover, New Hampshire, USA

**Lopa A. Mehta, MBBS, MS(Anatomy)**

Senior Professor, Department of Anatomy  
Seth G. S. Medical College  
Mumbai, India

**J. H. Meiring, MB, ChB, MpraxMed(Pret)**

Professor and Head, Department of  
Anatomy  
University of Pretoria  
Pretoria, South Africa

**Sandra C. Miller, PhD**

Professor, Department of Anatomy and  
Cell Biology  
McGill University  
Montreal, Quebec, Canada

**Ian G. Mobbs, PhD**

Associate Professor, Department of  
Anatomy and Neurobiology  
Dalhousie Medical School  
Halifax, Nova Scotia, Canada

**John F. Morris, MB, ChB, MD**

Professor, Department of Human  
Anatomy and Genetics  
University of Oxford  
Oxford, UK

**Bernard John Moxham**

Professor of Anatomy, Deputy Director  
and Head of Teaching  
Cardiff School of Biosciences  
Cardiff University  
Cardiff, UK

**Helen D. Nicholson, MB, ChB, BSc, MD**

Professor and Chair, Department of  
Anatomy and Structural Biology  
University of Otago  
Dunedin, New Zealand

**Mark Nielsen**

Biology Department  
University of Utah  
Salt Lake City, Utah, USA

**Wei-Yi Ong, DDS, PhD**

Associate Professor, Department of  
Anatomy  
Faculty of Medicine, National University of  
Singapore  
Singapore

**Gustavo H. R. A. Otegui**

Department of Anatomy  
University of Buenos Aires  
Buenos Aires, Argentina

**Reinhard Pabst**

Chair, Department of Functional and  
Applied Anatomy  
Medical School of Hanover  
Hanover, Germany

**Gigis Panagiotis, MD, PhD**

Professor, Department of Anatomy  
Medical School, Aristotle University of  
Thessaloniki  
Thessaloniki, Greece

**Shipra Paul**

Professor, Department of Anatomy  
Maulana Azad Medical College  
New Delhi, India

**Ann Poznanski, PhD**

Associate Professor, Department of  
Anatomy  
Midwestern University  
Glendale, Arizona, USA

**Francisco A. Prada Elena**

Chair, Department of Anatomy  
Faculty of Medicine, University of Sevilla  
Sevilla, Spain

**Matthew A. Pravetz, OFM, PhD**

Associate Professor, Department of Cell  
Biology and Anatomy  
New York Medical College  
Valhalla, New York, USA

**Reinhard Putz**

Professor of Anatomy  
Chairman  
Institute of Anatomy  
Ludwig-Maximilians-University  
Munich, Germany

**Ameed Raouf, MD, PhD**

Lecturer, Division of Anatomy and  
Department of Medical Education  
University of Michigan Medical School  
Ann Arbor, Michigan, USA

**James J. Reichtien, DO**

Professor, Division of Anatomy and  
Structural Biology  
Department of Radiology  
Michigan State University  
East Lansing, Michigan, USA

**Joy S. Reidenberg, PhD**

Associate Professor, Center for Anatomy  
and Functional Morphology  
Mount Sinai School of Medicine  
New York, New York, USA

**Rouel S. Roque, MD**

Associate Professor, Department of Cell  
Biology and Genetics  
University of North Texas Health Sciences  
Center  
Forth Worth, Texas, USA

**Domingo Ruano Gil**

Director, Department of Anatomy  
Faculty of Medicine, University of Central  
Barcelona  
Barcelona, Spain

# Editorial review board

**Myra Rufo, PhD**

Department of Anatomy and Cellular  
Biology  
Tufts University  
Boston, Massachusetts, USA

**Phillip Sambrook, MD, BS, LLB, FRACP**

Professor of Rheumatology  
University of Sydney  
Sydney, Australia

**Richard R. Schmidt, PhD**

Professor and Vice Chairman  
Department of Pathology, Anatomy and  
Cell Biology  
Thomas Jefferson University  
Philadelphia, Pennsylvania, USA

**Roger Searle, PhD**

Director, Anatomy and Clinical Skills  
School of Medical Education Development  
University of Newcastle upon Tyne  
Newcastle upon Tyne, UK

**Harumichi Seguchi, MD, PhD**

Professor and Chairman, Department of  
Anatomy and Cell Biology  
Kochi Medical School  
Kochi, Japan

**Mark F. Seifert, PhD**

Professor of Anatomy and Cell Biology  
Indiana University School of Medicine  
Indianapolis, Indiana, USA

**Sudha Seshayyan, MS**

Professor and Head, Department of  
Anatomy  
Stanely Medical College  
Chennai, India

**Kohei Shiota, MD, PhD**

Professor and Chairman, Department of  
Anatomy and Developmental Biology  
Director, Congenital Anomaly Research  
Center  
Kyoto University Graduate School of  
Medicine  
Kyoto, Japan

**Allan R. Sinning, PhD**

Associate Professor, Department of  
Anatomy  
The University of Mississippi Medical  
Center  
Jackson, Mississippi, USA

**K. H. Sit, MBBS, MD, PhD**

Professor, Department of Anatomy  
Faculty of Medicine, National University of  
Singapore  
Singapore

**Donald F. Siwek, PhD**

Assistant Professor, Department of  
Anatomy and Neurobiology  
Boston University School of Medicine  
Boston, Massachusetts, USA

**Panagiotis N. Skandalakis**

Clinical Professor, Department of Surgical  
Anatomy and Technique  
Emory University  
Atlanta, Georgia, USA

**Bernard G. Slavin, PhD**

Course Director, Human Gross Anatomy  
Keck/University of Southern California  
School of Medicine  
Los Angeles, California, USA

**Terence K. Smith, PhD**

Professor, Department of Physiology and  
Cell Biology  
University of Nevada School of Medicine  
Reno, Nevada, USA

**Kwok-Fai So, PhD(MIT)**

Professor and Head, Department of  
Anatomy  
Faculty of Medicine  
The University of Hong Kong  
Hong Kong, China

**Roger Soames, BSc, PhD**

Associate Professor and Head of Anatomy  
School of Biomedical Sciences  
James Cook University  
Townsville, Australia

**Susan M. Standing, PhD, DSc**

Head of the Division of Anatomy  
Guy's, King's and St. Thomas' Schools of  
Medicine  
London, UK

**Mark D. Stringer MS, FRCP, FRCS, FRCSEd**

Professor of Anatomy  
Dept of Anatomy & Structural Biology  
Otago School of Medical Sciences  
University of Otago  
Dunedin, New Zealand

**Mark F. Teaford, PhD**

Professor of Anatomy, Center for  
Functional Anatomy and Evolution  
Johns Hopkins University School of  
Medicine  
Baltimore, Maryland, USA

**Don du Toit, PPhil(Oxon), PhD,  
MB.CHB(Stell), FCS(SA), FRCS**

Professor and Chairman, Department of  
Anatomy and Histology  
Faculty of Medicine  
University of Stellenbosch  
Bellville, South Africa

**John Varakis**

Anatomy Department  
University of Patras School of Medicine  
Rion Patras, Greece

**N. S. Vasan, DVM, PhD**

Associate Professor, Department of Cell  
Biology and Molecular Medicine  
New Jersey Medical School  
Newark, New Jersey, USA

**G. H. M. Vawda**

Anatomy Department  
Nelson Mandela Medical School  
Congella, South Africa

**Ismo Virtanen**

Professor, Anatomy Department  
Haartman Institute  
University of Helsinki  
Helsinki, Finland

**Shashi Wadhwa, MS(Anatomy), PhD,  
FASC, FNASc**

Professor, Department of Anatomy  
All India Institute of Medical Sciences  
New Delhi, India

**Anil H. Walji, MD, PhD**

Chair, Division of Anatomy  
Faculty of Medicine and Dentistry  
University of Alberta  
Edmonton, Alberta, Canada

**Joanne Wilton**

Senior Lecturer, Department of Anatomy  
The Medical School  
University of Birmingham  
Birmingham, UK

**Susanne Wish-Baratz, PhD**

Senior Instructor  
Department of Anatomy  
Case Western Reserve University School of  
Medicine  
Cleveland, Ohio, USA

**David T. Yew, PhD, DSc, DrMed(Habil),  
CBiol, FIBiol**

Professor and Chairman  
Department of Anatomy  
The Chinese University of Hong Kong  
Hong Kong, China

**Henry K. Yip, PhD**

Associate Professor  
Department of Anatomy  
Faculty of Medicine  
The University of Hong Kong  
Hong Kong, China

# Acknowledgments

First, we would like to collectively thank those who agreed to examine earlier drafts of the book—anatomists, educators, and student members of the editorial review board from around the world. Your input was invaluable.

We'd also like to thank Richard Tibbitts and Paul Richardson for their skill in turning our visual ideas into a reality that is not only a foundation for the acquisition of anatomical knowledge, but also is beautiful.

Thanks must also go to Bill Schmitt, Rebecca Grulow, Frank Morales and all the team at Elsevier for guiding us through the preparation of this book.

We'd also like to thank Professor Richard A. Buckingham of the Abraham Lincoln School of Medicine, University of Illinois for the provision of Fig. 8.109B. Finally, because we worked separately, distanced by, in some cases, thousands of miles, there are various people who gave local support, whom we would like to make mention of individually. We've gratefully listed them here:

Dr Leonard Epp, Dr Carl Morgan, Dr Robert Shellhamer, and Dr Robert Cardell who profoundly influenced my career as a scientist and an educator.

*Richard L. Drake*

Dr Sydney Friedman, Dr Elio Raviola, and Dr Charles Slonecker, for their inspiration and support, and for instilling in me a passion for the discipline of Anatomy;

Dr Murray Morrison, Dr Joanne Matsubara, Dr Brian Westerberg, Laura Hall, and Jing Cui, for contributing images for the chapter on the head and neck; and Dr Bruce Crawford and Logan Lee, for help with images for the surface anatomy of the upper limb.

Professor Elizabeth Akesson and Dr Donna Ford, for their enthusiastic support and valuable critiques.

*A. Wayne Vogl*

Anne Gayle, for her unsurpassed secretarial support; Professor Philip Gizhen, for help in sourcing images, and his general support;

Dr Dominic Blunt and Chrissie Hill, for assistance in providing images;

Dr Mareesh Patel, for help with reading manuscripts and with the clinical questions;

Radiology SpRs and radiographers at the Charing Cross Hospital;

Radiographers at the Wellington Hospital;

Dr Anwar Padhani, at the Mount Vernon Hospital;

Dr Alison Graham and Dr Paul Tait, at the Hammer-smith Hospital; and

Mr Andrew Williams, at the Chelsea and Westminster Hospital.

Dr Neil Fraser, Dr Martin Watson, Dr Kim Fox, Dr Jerry Healy, Dr James Jackson, and Mr Ian Franklin also deserve my thanks.

*Adam W. M. Mitchell*

# Dedications

To my wife, Cheryl,  
who has supported me;  
and my parents who have guided me.

*Richard L. Drake*

To my family,  
to my professional colleagues  
and role models,  
and to my students—  
this book is for you.

*A. Wayne Vogl*

To Cathy, Max (Adder),  
and Elsa (ZaZa).

*Adam W. M. Mitchell*

# Preface

The first edition of *Gray's Anatomy for Students* accomplished many of the goals we had established for this textbook, including our primary goal of helping students learn anatomy. However, we realized from the many suggestions, comments, and kind advice we received from colleagues and students around the world that there were modifications and changes that would improve this textbook. So keeping in mind the goals and objectives of the first edition, we began work on the second edition by evaluating all of the input from our readers, assessing changes occurring in the educational environment, and doing our best to predict the future direction of anatomy education. The result is the second edition of *Gray's Anatomy for Students*, which builds on the past and looks toward the future.

One of the most significant changes in the second edition of our textbook occurs in Chapter 1. This chapter has been retitled “The Body” and not only includes the material from Chapter 1 of the first edition, such as “What is anatomy?” and “Imaging” but also has a new section, entitled “Body systems.” This new section provides students with an overview of the skeletal system, skin and fascias, the muscular system, the cardiovascular system, the lymphatic system (material moved from Chapter 4 of the previous edition), and the nervous system (material moved from Chapter 2 of the first edition). The information is concise in its presentation, and its clinical significance is emphasized by the addition of numerous examples of common clinical problems.

Another significant change in this edition involves the presentation of clinical material. While “In the Clinic”

boxes are still presented throughout the textbook, usually at the end of a section of material so as not to destroy the readability of the textbook, we have also highlighted clinically relevant information throughout the textual material. This technique, while maintaining the book's readability, provides the student with a rapid locator of clinical “pearls of wisdom.” Thus, throughout the textbook, boxes in pastel green and text highlighted in gray signal clinical information—pay particular attention.

Finally, the index has been completely restructured and provides the reader with a more convenient and useful tool for finding information. We have also added a concise table of contents at the beginning of each chapter to further assist the reader in the location of specific topics. Additionally, a large number of the clinical images and pictures used in the first edition have been upgraded. Many of them have been replaced with higher quality examples and imaging from newly emerging technologies. Smaller changes in this second edition include modifying some of the artwork, adding some new artwork, and moving the 10 short questions at the end of each chapter to Student Consult online.

We feel that with these changes the second edition of *Gray's Anatomy for Students* is a much improved version of the first edition, and we hope that the book will continue to be a valuable learning resource for students.

*Richard L. Drake*  
*A. Wayne Vogl*  
*Adam W. M. Mitchell*  
January 2009

# Preface

This page intentionally left blank

# About the book

## The idea

In the past 20 years or so, there have been many changes that have shaped how students learn human anatomy in medical and dental schools and in allied health programs, with curricula becoming either more integrated or more systems based. In addition, instructional methods focus on the use of small group activities with the goals of increasing the amount of self-directed learning, and acquiring the skills for the life-long acquisition of knowledge. An explosion of information in every discipline has also been a force in driving curricular change as it increases the amount to be learned without necessarily increasing the time available. With these changes, we felt it was time for a new text to be written that would allow students to learn anatomy within the context of many different curricular designs, and within ever-increasing time constraints.

We began in the fall of 2001 by considering the various approaches and formats that we might adopt, eventually deciding upon a regional approach to anatomy with each chapter having four sections. From the beginning, we wanted the book to be designed with multiple entry points, to be targeted at introductory level students in a broad spectrum of fields, and to be a student-oriented companion text for *Gray's Anatomy*, which is aimed at a more professional audience. We wrote the text first and subsequently constructed all the artwork and illustrations to complement and augment the words. Preliminary drafts of chapters, when complete, were distributed to an international editorial board of anatomists, educators, and anatomy students for review. Their comments were then considered carefully in the preparation of the final book.

The text is not meant to be exhaustive in coverage, but to present enough anatomy to provide students with a structural and functional context in which to add further detail as they progress through their careers. *Gray's Anatomy* was used as the major reference, both for the text and for the illustrations, during the preparation of this book, and it is the recommended source for acquiring additional detail.

## The book

*Gray's Anatomy for Students* is a clinically oriented, student-friendly textbook of human anatomy. It has been prepared

primarily for students in a variety of professional programs (e.g., medical, dental, chiropractic, and physical therapy programs). It can be used by students in traditional, systemic, combined traditional/systemic, and problem-based curricula and will be particularly useful to students when lectures and laboratories in gross anatomy are minimal.

## Organization

Using a regional approach, *Gray's Anatomy for Students* progresses through the body in a logical fashion, building on the body's complexities as the reader becomes more comfortable with the subject matter. Each chapter can be used as an independent learning module, and varying the sequence will not affect the quality of the educational experience. The sequence we have chosen to follow is back, thorax, abdomen, pelvis and perineum, lower limb, upper limb and head and neck.

We begin with the back because it is often the initial area dissected by students. The thorax is next because of its central location and its contents (i.e., the heart, the great vessels, and the lungs). This also begins a progression through the body's cavities. The abdomen and pelvis and perineum follow logically in sequence from the thorax. Continuing downward toward the feet, the lower limb is next, followed by the upper limb. The last region discussed is the head and neck. This region contains some of the most difficult anatomy in the body. Covering all other regions first gives the student the opportunity to build a strong foundation from which to understand this complex region.

## Content

Each regional anatomy chapter consists of four consecutive sections: conceptual overview, regional anatomy, surface anatomy, and clinical cases.

The conceptual overview provides the basis on which information in the later sections is built. This section can be read independently of the rest of the text by students who require only a basic level of understanding and can also be read as a summary of important concepts after the regional anatomy has been mastered.

The regional anatomy section provides more detailed anatomy along with a substantial amount of relevant clinical correlations. It is not an exhaustive discussion

## About the book

but instead provides information to a level that we feel is necessary for understanding the organization of the region. Throughout this section, two levels of clinical material are provided. Clinical hooks are fully integrated with the main anatomical text and function to relate (“hook”) the anatomy discussed directly to a clinical application without taking students out of their train of thought and without disrupting the flow of the text. Although fully integrated with the anatomical text, these passages are differentiated from it by the use of green highlighting. “In the Clinic” summaries provide students with useful and relevant clinical information demonstrating how applying anatomical knowledge facilitates the solving of clinical problems. These are spread throughout the text close to the most relevant anatomical discussion.

Surface anatomy assists students in visualizing the relationship between anatomical structures and surface landmarks. This section also provides students with practical applications of the anatomical information, combining visual inspection with functional assessment, as occurs during any type of patient examination.

The final section of each chapter consists of clinical cases. These cases represent the third level of clinical material in the book. In these cases the clinical problem is described, and a step-by-step process of questions and answers leads the reader to the resolution of the case. The inclusion of these cases in each chapter provides students with the opportunity to apply an understanding of anatomy to the resolution of a clinical problem.

Illustrations are an integral part of any anatomy text. They must present the reader with a visual image that brings the text to life and presents views that will assist in the understanding and comprehension of the anatomy. The artwork in this text accomplishes all of these goals. The illustrations are original and vibrant, and many views are unique. They have been designed to integrate with the text, present the anatomy in new ways, deal with the issues that students find particularly difficult, and provide a conceptual framework for building further understanding. To ensure that the illustrations of the book work together and to enable students to cross-refer from one illustration to another, we have used standard colors throughout the book, except where indicated otherwise.



artery



vein



nerve



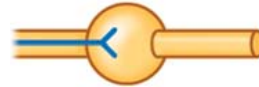lymphatic



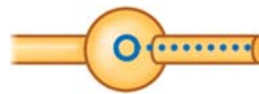sympathetic fiber



parasympathetic fiber



preganglionic fiber (solid)



postganglionic fiber (dotted)

The position and size of the artwork was one of the parameters considered in the overall design of each page of the book.

Clinical images are also an important tool in understanding anatomy and are abundant throughout the text. Examples of state-of-the-art medical imaging, including MRIs, CTs, PETs, and ultrasound as well as high-quality radiographs, provide students with additional tools to increase their ability to visualize anatomy in vivo and, thus, increase their understanding.

### What the book does not contain

*Gray's Anatomy for Students* focuses on gross anatomy. While many curricula around the world are being presented in a more integrated format combining anatomy, physiology, histology, and embryology, we have focused this textbook on understanding only the anatomy and its application to clinical problems. Except for some brief references to embryology where necessary for a better understanding of the anatomy, material from other disciplines is not included. We felt that there are many outstanding textbooks covering these subject areas, and that trying to cover everything in a single book would produce a text of questionable quality and usefulness, not to mention enormous size!

## Terminology

In any anatomical text or atlas, terminology is always an interesting issue. In 1989, the Federative Committee on Anatomical Terminology (FCAT) was formed and was charged with developing the official terminology of

the anatomical sciences. The *Terminologia Anatomica* (Thieme, Stuttgart/New York, 1998) was a joint publication by this group and the 56 member associations of the International Federation of Associations of Anatomists (IFAA). We have chosen to use the terminology presented in this publication in the interest of uniformity. Other terminology is not incorrect; we just felt that using terminology from this single, internationally recognized source would be the most logical and straightforward approach.

Although we use anatomical terms for orientation as much as possible, we also use terms such as “behind” or “in front of” occasionally to make the text more readable. In these cases, the context clarifies the meaning.

### **Anatomical use of adverbs**

During the writing of this book, we had many long discussions about how we were going to describe anatomical relationships as clearly as possible, but maintain the readability of the text. One issue that arose continually in our discussions was the correct use of the “-ly” adverb form of anatomical orientation terms, such as anterior, posterior, superior, inferior, lateral, and medial. We reached the following consensus:

**-ly adverbs** *e.g., anteriorly, posteriorly*, have been used to modify (describe) verbs in passages where an action or direction is mentioned. For example, “The trachea passes inferiorly through the thorax.”

**circumstantial adverbs**, *e.g., anterior, posterior*, have been used to indicate the fixed location of an anatomical feature. For example, “The trachea is anterior to the esophagus.”

Furthermore, both usages may occur in the same passage. For example, “The trachea passes inferiorly through the thorax, anterior to the esophagus.”

We have very much enjoyed the process of putting this book together. We hope that you enjoy using it to the same degree.

*Richard L. Drake  
A. Wayne Vogl  
Adam W. M. Mitchell  
January 2009*

# Index of clinical content

## 1 **The body**

### In the Clinic

- Determination of skeletal age 16
- Bone marrow transplants 17
- Bone fractures 18
- Avascular necrosis 18
- Osteoporosis 19
- Epiphyseal fractures 20
- Degenerative joint disease 24
- Joint replacement 26
- The importance of fascias 27
- Muscle paralysis 28
- Muscle atrophy 28
- Muscle injuries and strains 28
- Atherosclerosis 29
- Varicose veins 30
- Anastomoses and collateral circulation 30
- Lymph nodes 33
- Dermatomes and myotomes 40
- Referred pain 52

### Clinical Case

- Appendicitis 53

## 2 **Back**

### In the Clinic

- Spina bifida 76
- Vertebroplasty 77
- Scoliosis 77
- Kyphosis 78
- Variation in vertebral numbers 78
- The vertebrae and cancer 79
- Osteoporosis 79
- Back pain 81
- Herniation of intervertebral discs 81
- Joints 82
- Ligamenta flava 84
- Vertebral fractures 84
- Pars interarticularis fractures 85
- Surgical procedures on the back 86
- Spinal fusion 86

- Nerve injuries affecting superficial back muscles 101
- Lumbar cerebrospinal fluid tap 108
- Herpes zoster 110
- Back pain—alternative explanations 111

### Clinical Cases

- Sciatica versus lumbago 118
- Cervical spinal cord injury 118
- Psoas abscess 119
- Dissecting thoracic aneurysm 119
- Sacral tumor 121

## 3 **Thorax**

### In the Clinic

- Breast cancer 139
- Cervical ribs 147
- Collection of sternal bone marrow 147
- Rib fractures 147
- Surgical access to the chest 156
- Chest drain (tube) insertion 156
- Imaging the lungs 174
- High-resolution lung CT 174
- Bronchoscopy 174
- Lung cancer 175
- Pericarditis 179
- Pericardial effusion 179
- Constrictive pericarditis 180
- Valve disease 191
- Clinical terminology for coronary arteries 194
- Coronary artery disease 196
- Common congenital heart defects 197
- Cardiac auscultation 197
- Cardiac conduction system 200
- Ectopic parathyroid glands in the thymus 206
- Venous access for central and dialysis lines 208
- Using the superior vena cava to access the inferior vena cava 209
- Coarctation of the aorta 210
- Thoracic aorta 210
- Aortic arch and its anomalies 211

Abnormal origin of great vessels 211  
 The vagus nerves, recurrent laryngeal nerves, and hoarseness 214  
 Esophageal cancer 217  
 Esophageal rupture 217

## Clinical Cases

Cervical rib 233  
 Lung cancer 234  
 Chest wound 234  
 Myocardial infarction 235  
 Broken pacemaker 238  
 Coarctation of the aorta 238  
 Aortic dissection 239  
 Pneumonia 240  
 Esophageal cancer 241  
 Venous access 242

## **4** **Abdomen**

### In the Clinic

Surgical incisions 269  
 Cremasteric reflex 288  
 Masses around the groin 290  
 Inguinal hernias 290  
 Femoral hernias 291  
 Umbilical hernias 291  
 Incisional hernias 291  
 Other hernias 291  
 Peritoneum 294  
 Ventriculoperitoneal shunts 294  
 Dialysis and peritoneal dialysis 294  
 Peritoneal spread of disease 294  
 The greater omentum 296  
 Epithelial transition between the abdominal esophagus and stomach 303  
 Duodenal ulceration 303  
 Examination of the upper gastrointestinal tract 304  
 Examination of the bowel lumen 304  
 Examination of the bowel wall and extrinsic masses 304  
 Meckel's diverticulum 306  
 Computed tomography (CT) scanning and magnetic resonance imaging (MRI) 306  
 Advanced imaging methods 306  
 Carcinoma of the stomach 306  
 Appendicitis 310  
 Congenital disorders of the gastrointestinal tract 313  
 Malrotation and midgut volvulus 313  
 Bowel obstruction 314

Diverticular disease 315  
 Ostomies 315  
 Gastrostomy 315  
 Jejunostomy 315  
 Ileostomy 316  
 Colostomy 316  
 Ileal conduit 316  
 Annular pancreas 322  
 Segmental anatomy of the liver 325  
 Gallstones 326  
 Jaundice 326  
 Spleen disorders 327  
 Vascular supply to the gastrointestinal system 336

Hepatic cirrhosis 339  
 Portosystemic anastomosis 339  
 Surgery for obesity 347  
 Psoas muscle abscess 353  
 Diaphragmatic hernias 354  
 Hiatus hernia 355  
 Urinary tract stones 361  
 Urinary tract cancer 361  
 Nephrostomy 363  
 Kidney transplant 364  
 Investigation of the urinary tract 366  
 Abdominal aortic stent graft 369  
 Inferior vena cava filter 371  
 Retroperitoneal lymph node surgery 373

### Clinical Cases

Traumatic rupture of the diaphragm 391  
 Chronic thrombosis of the inferior vena cava 391  
 Liver biopsy in patients with suspected liver cirrhosis 392  
 Hodgkin's lymphoma 393  
 Inguinal hernia 394  
 Ureteric stone 395  
 Intra-abdominal abscess 395  
 Complications of an abdominoperineal resection 396  
 Carcinoma of the head of the pancreas 398  
 Caval obstruction 399  
 Diverticular disease 400  
 Endoleak after endovascular repair of abdominal aortic aneurysm 401  
 Gastrointestinal bleed 401  
 Metastatic lesions in the liver 403

## **5** **Pelvis and perineum**

### In the Clinic

Locating the position of the femoral artery 421

# Index of clinical content

Using the femoral artery for angiography and endovascular procedures 421  
Using the femoral vein for pulmonary angiography 421  
Bone marrow biopsy 424  
Pelvic fracture 426  
Common problems with the sacro-iliac joints 428  
Pelvic measurements in obstetrics 433  
Defecation 435  
Episiotomy 439  
Digital rectal examination 439  
Carcinoma of the colon and rectum 441  
Bladder stones 443  
Suprapubic catheterization 443  
Bladder cancer 444  
Bladder infection 446  
Urethral catheterization 447  
Testicular tumors 448  
Vasectomy 450  
Prostate problems 451  
Ovarian cancer 455  
Imaging the ovary 455  
Hysterectomy 456  
Tubal ligation 457  
Carcinoma of the cervix and uterus 457  
The recto-uterine pouch 460  
Pudendal block 466  
Prostatectomy and impotence 471  
Abscesses in the ischio-anal fossae 480  
Hemorrhoids 482  
Urethral rupture 490

Clinical Cases  
Varicocele 504  
Sciatic nerve compression 505  
Pelvic kidney 505  
Left common iliac artery obstruction 506  
Iatrogenic ureteric injury 507  
Ectopic pregnancy 508  
Uterine tumor 509

## 6 Lower limb

In the Clinic  
Pelvic fractures 528  
Blood supply to the femoral head and neck 532  
Femoral neck fractures 532  
Femoral shaft fracture 532  
Varicose veins 544

Deep vein thrombosis 544  
Vascular access to the lower limb 547  
Intramuscular injections 553  
Muscle injuries to the lower limb 569  
Peripheral vascular disease 572  
Chronic leg ischemia 572  
Acute on chronic ischemia 572  
Critical limb ischemia 572  
Soft tissue injuries to the knee 582  
Degenerative joint disease/osteoarthritis 582  
Examination of the knee joint 583  
Neurological examination of the legs 592  
Fracture of the talus 606  
Midfoot fractures 606  
Ankle fractures 608  
Bunions 611  
Morton's neuroma 626

Clinical Cases  
Varicose veins 638  
Knee joint injury 639  
Fracture of neck of femur 642  
Deep vein thrombosis 643  
Ruptured calcaneal tendon 644  
Popliteal artery aneurysm 645  
Anterior talofibular ligament tear 646

## 7 Upper limb

In the Clinic  
Fracture of the proximal humerus 668  
Fractures of the clavicle and dislocations of the acromioclavicular and sternoclavicular joints 673  
Dislocations of the glenohumeral joint 674  
Rotator cuff disorders 675  
Quadrangular space syndrome 682  
Damage to the long thoracic nerve 690  
Imaging the blood supply to the upper limb 698  
Trauma to the arteries of the upper limb 699  
Fracture of rib I 699  
Anterior dislocation of the humeral head 699  
Subclavian pinch-off syndrome 699  
Injuries to the brachial plexus 709  
Breast cancer 711  
Rupture of biceps tendon 716  
Blood pressure measurement 720  
Radial nerve injury in the arm 724  
Median nerve injury in the arm 724

Elbow joint injury 727  
 Supracondylar fracture of the humerus 728  
 Transection of the radial or ulnar arteries 728  
 Pulled elbow 728  
 Fracture of the head of radius 728  
 Epicondylitis 728  
 Elbow arthritis 729  
 Ulnar nerve injury 729  
 Construction of a dialysis fistula 731  
 Fractures of the radius and ulna 734  
 Fracture of the scaphoid and avascular necrosis of the proximal scaphoid 756  
 Carpal tunnel syndrome 758  
 Snuffbox 759  
 Allen's test 770  
 Venipuncture 770  
 Ulnar nerve injury 772  
 Radial nerve injury 774

## Clinical Cases

Shoulder problem after falling on an outstretched hand 786  
 Winged scapula 786  
 Brachial plexus nerve block 787  
 Complication of a fractured first rib 787  
 Carpal tunnel syndrome 788  
 Immobilizing extensor digitorum 789  
 Torn supraspinatus tendon 789  
 How to examine the hand 790  
 Shoulder joint problem 791

## **8** **Head and neck**

### In the Clinic

Medical imaging of the head 828  
 Fractures of the skull vault and extradural hematoma 829  
 Depressed skull fractures 829  
 Compound fractures 829  
 Pterion fractures 829  
 Hydrocephalus 834  
 Meningitis 835  
 Brain tumors 835  
 Stroke 839  
 Intracerebral aneurysms 840

Head injury 845  
 Types of intracranial hemorrhage 845  
 Clinical assessment of patients with head injury 847  
 Treatment of head injury 847  
 Cranial nerve lesions 855  
 Parotid gland 865  
 Facial nerve [VII] palsy (Bell's palsy) 872  
 Central lesions 872  
 Lesions at and around the geniculate ganglion 872  
 Lesions at and around the stylomastoid foramen 872  
 Trigeminal neuralgia 873  
 Scalp laceration 877  
 Horner's syndrome 882  
 Surgically-induced Horner's syndrome 882  
 Examination of the eye 892  
 Loss of innervation of the muscles around the eye 892  
 Glaucoma 899  
 Cataracts 899  
 Ophthalmoscopy 900  
 Examination of the ear 905  
 Tympanic membrane perforation 906  
 Mastoiditis 909  
 Lingual nerve injury 935  
 Dental anesthesia 937  
 Fascial planes of the head and neck 952  
 Central venous access 953  
 Jugular venous pulse 961  
 Thyroid gland 967  
 Thyroidectomy 967  
 Thyroid gland pathology 968  
 Clinical lymphatic drainage of the head and neck 985  
 Tracheostomy 1009

### Clinical Cases

Multinodular goiter 1071  
 Parotid duct calculus 1072  
 Extradural hematoma 1073  
 Stenosis of the internal carotid artery 1074  
 Posterior communicating artery aneurysm 1075  
 Recurrent epistaxis 1076  
 Complication of orbital fracture 1077  
 Brainstem tumor 1078  
 Pituitary macroadenoma 1079

This page intentionally left blank

# Contents

## 1 The body

### What is anatomy? 4

*How can gross anatomy be studied?* 4

*Important anatomical terms* 4

### Imaging 7

*Diagnostic imaging techniques* 7

*Nuclear medicine imaging* 10

### Image interpretation 11

*Plain radiography* 12

*Computed tomography* 12

*Magnetic resonance imaging* 13

*Nuclear medicine imaging* 13

### Safety in imaging 13

### Body systems 14

*Skeletal system* 14

Cartilage 14

Bone 15

Joints 20

*Skin and fascias* 26

Skin 26

Fascia 26

*Muscular system* 27

*Cardiovascular system* 29

*Lymphatic system* 31

Lymphatic vessels 31

Lymph nodes 32

Lymphatic trunks and ducts 32

*Nervous system* 34

Central nervous system 34

Functional subdivisions of the CNS 34

*Somatic part of the nervous system* 35

*Visceral part of the nervous system* 41

*Other systems* 52

### Clinical cases 53

## 2 Back

### Conceptual overview 56

*General description* 56

*Functions* 57

Support 57

Movement 57

Protection of the nervous system 58

*Component parts* 58

Bones 58

Muscles 60

Vertebral canal 62

Spinal nerves 63

*Relationship to other regions* 64

Head 64

Thorax, abdomen, and pelvis 65

Limbs 65

*Key features* 65

Long vertebral column and short spinal cord 65

Intervertebral foramina and spinal nerves 66

Innervation of the back 66

### Regional anatomy 67

*Skeletal framework* 67

Vertebrae 67

Intervertebral foramina 75

Posterior spaces between vertebral arches 75

*Joints* 79

Joints between vertebrae in the back 79

*Ligaments* 82

Anterior and posterior longitudinal ligaments 82

Ligamenta flava 82

Supraspinous ligament and ligamentum  
nuchae 83

Interspinous ligaments 84

*Back musculature* 86

Superficial group of back muscles 86

Intermediate group of back muscles 92

Deep group of back muscles 93

Suboccipital muscles 99

### Spinal cord 101

Vasculature 102

Meninges 104

Arrangement of structures in the vertebral  
canal 106

Spinal nerves 107

## Surface anatomy 112

- Back surface anatomy 112
- Absence of lateral curvatures 112
- Primary and secondary curvatures in the sagittal plane 112
- Useful nonvertebral skeletal landmarks 112
- How to identify specific vertebral spinous processes 114
- Visualizing the inferior ends of the spinal cord and subarachnoid space 115
- Identifying major muscles 116

## Clinical cases 118

### 3

## Thorax

## Conceptual overview 124

### General description 124

### Functions 125

- Breathing 125
- Protection of vital organs 125
- Conduit 125

### Component parts 125

- Thoracic wall 125
- Superior thoracic aperture 126
- Inferior thoracic aperture 126
- Diaphragm 127
- Mediastinum 128
- Pleural cavities 128

### Relationship to other regions 129

- Neck 129
- Upper limb 130
- Abdomen 130
- Breast 130

### Key features 130

- Vertebral level TIV/V 130
- Venous shunts from left to right 132
- Segmental neurovascular supply of thoracic wall 132
- Sympathetic system 134
- Flexible wall and inferior thoracic aperture 134
- Innervation of the diaphragm 134

## Regional anatomy 137

### Pectoral region 137

- Breast 137
- Muscles of the pectoral region 139

### Thoracic wall 141

- Skeletal framework 141
- Intercostal spaces 147

### Diaphragm 156

- Venous drainage 158
- Innervation 158

### Movements of the thoracic wall and diaphragm during breathing 158

### Pleural cavities 159

- Pleura 159
- Lungs 163

## Mediastinum 176

- Middle mediastinum 177
- Superior mediastinum 204
- Posterior mediastinum 215
- Anterior mediastinum 223

## Surface anatomy 224

- Thorax surface anatomy 224
- How to count ribs 224
- Surface anatomy of the breast in women 225
- Visualizing structures at the TIV/V vertebral level 226
- Visualizing structures in the superior mediastinum 227
- Visualizing the margins of the heart 227
- Where to listen for heart sounds 228
- Visualizing the pleural cavities and lungs, pleural recesses, and lung lobes and fissures 228
- Where to listen for lung sounds 229

## Clinical cases 233

### 4

## Abdomen

## Conceptual overview 246

### General description 246

### Functions 247

- Houses and protects major viscera 247
- Breathing 249
- Changes in intra-abdominal pressure 249

### Component parts 250

- Wall 250
- Abdominal cavity 251
- Inferior thoracic aperture 253
- Diaphragm 253
- Pelvic inlet 254

### Relationship to other regions 254

- Thorax 254
- Pelvis 254
- Lower limb 255

### Key features 256

- Arrangement of abdominal viscera in the adult 256

Skin and muscles of the anterior and lateral abdominal wall and thoracic intercostal nerves 259  
 The groin is a weak area in the anterior abdominal wall 260  
 Vertebral Level L1 262  
 The gastrointestinal system and its derivatives are supplied by three major arteries 262  
 Venous shunts from left to right 264  
 All venous drainage from the gastrointestinal system passes through the liver 265  
 Abdominal viscera are supplied by a large prevertebral plexus 266

## Regional anatomy 268

### Surface topography 268

Four-quadrant pattern 268  
 Nine-region pattern 269

### Abdominal wall 270

Superficial fascia 270  
 Anterolateral muscles 272  
 Extraperitoneal fascia 278  
 Peritoneum 279  
 Innervation 279  
 Arterial supply and venous drainage 280  
 Lymphatic drainage 282

### Groin 282

Inguinal canal 284  
 Inguinal hernias 288

### Abdominal viscera 292

Peritoneum 292  
 Peritoneal cavity 293  
 Organs 297  
 Arterial supply 327  
 Venous drainage 337  
 Lymphatics 341  
 Innervation 341

### Posterior abdominal region 348

Posterior abdominal wall 349  
 Viscera 355  
 Vasculature 366  
 Lymphatic system 372  
 Nervous system in the posterior abdominal region 374  
 Sympathetic trunks and splanchnic nerves 374

## Surface anatomy 382

Abdomen surface anatomy 382  
 Defining the surface projection of the abdomen 383  
 How to find the superficial inguinal ring 384  
 How to determine lumbar vertebral levels 385  
 Visualizing structures at the L1 vertebral level 386

Visualizing the position of major blood vessels 387  
 Using abdominal quadrants to locate major viscera 388  
 Defining surface regions to which pain from the gut is referred 389  
 Where to find the kidneys 390  
 Where to find the spleen 390

## Clinical cases 391

# 5

## Pelvis and perineum

### Conceptual overview 406

#### General description 406

#### Functions 406

Contain and support bladder, rectum, anal canal, and reproductive tracts 406  
 Anchors the roots of the external genitalia 408

#### Component parts 408

Pelvic inlet 408  
 Pelvic walls 409  
 Pelvic outlet 409  
 Pelvic floor 411  
 Pelvic cavity 411  
 Perineum 412

#### Relationship to other regions 414

Abdomen 414  
 Lower limb 414

#### Key features 415

The pelvic cavity projects posteriorly 415  
 Important structures cross the ureters in the pelvic cavity 415  
 The prostate is anterior to rectum 417  
 The perineum is innervated by sacral spinal cord segments 417  
 Nerves are related to bone 418  
 Parasympathetic innervation from spinal cord levels S2 to S4 controls erection 418  
 Muscles and fascia of the pelvic floor and perineum intersect at the perineal body 419  
 Gender determines the course of the urethra 419

## Regional anatomy 421

### Pelvis 421

Bones 421  
 Joints 426  
 Orientation 428  
 Gender differences 428  
 True pelvis 429  
 Viscera 438

# Contents

Fascia 458  
Peritoneum 460  
Nerves 462  
Blood vessels 471  
Lymphatics 477

## **Perineum 478**

Borders and ceiling 478  
Ischio-anal fossae and their anterior recesses 480  
Anal triangle 480  
Urogenital triangle 483  
Somatic nerves 490  
Visceral nerves 492  
Blood vessels 492  
Veins 494  
Lymphatics 496

## **Surface anatomy 497**

Surface anatomy of the pelvis and perineum 497  
Orientation of the pelvis and perineum in the anatomical position 497  
How to define the margins of the perineum 497  
Identification of structures in the anal triangle 499  
Identification of structures in the urogenital triangle of women 500  
Identification of structures in the urogenital triangle of men 501

## **Clinical cases 504**

## **6 Lower limb**

### **Conceptual overview 512**

*General introduction* 512

*Function* 513

Support the body weight 513  
Locomotion 515

*Component parts* 517

Bones and joints 517  
Muscles 518

*Relationship to other regions* 520

Abdomen 520  
Pelvis 521  
Perineum 521

*Key points* 521

Innervation is by lumbar and sacral spinal nerves 521  
Nerves related to bone 525  
Superficial veins 525

*Regional anatomy* 526

Bony pelvis 526  
Proximal femur 529

Hip joint 532  
Gateways to the lower limb 535  
Nerves 537  
Arteries 540  
Veins 542  
Lymphatics 542  
Deep fascia and the saphenous opening 544  
Femoral triangle 545

### **Gluteal region 547**

Muscles 548  
Nerves 551  
Arteries 554  
Veins 554  
Lymphatics 554

### **Thigh 555**

Bones 555  
Muscles 561  
Arteries 569  
Veins 573  
Nerves 573  
Knee joint 575  
Tibiofibular joint 584  
Popliteal fossa 584

### **Leg 585**

Bones 586  
Joints 588  
Posterior compartment of leg 588  
Lateral compartment of leg 595  
Anterior compartment of leg 596

### **Foot 600**

Bones 600  
Joints 605  
Tarsal tunnel, retinacula, and arrangement of major structures at the ankle 612  
Arches of the foot 614  
Plantar aponeurosis 615  
Fibrous sheaths of toes 615  
Extensor hoods 616  
Intrinsic muscles 616  
Arteries 622  
Veins 624  
Nerves 624

### **Surface anatomy 628**

Lower limb surface anatomy 628  
Avoiding the sciatic nerve 628  
Finding the femoral artery in the femoral triangle 630  
Identifying structures around the knee 630  
Visualizing the contents of the popliteal fossa 632  
Finding the tarsal tunnel—the gateway to the foot 633  
Identifying tendons around the ankle and in the foot 634

Finding the dorsalis pedis artery 635  
 Approximating the position of the plantar arterial arch 635  
 Major superficial veins 636  
 Pulse points 637

**Clinical cases 638**

**7 Upper limb**

**Conceptual overview 650**

*General description 650*

*Functions 651*

Positioning the hand 651  
 The hand as a mechanical tool 651  
 The hand as a sensory tool 654

*Component parts 654*

Bones and joints 654  
 Muscles 655

*Relationship to other regions 657*

Neck 657  
 Back and thoracic wall 658

*Key points 659*

Innervation by cervical and upper thoracic nerves 659  
 Nerves related to bone 663  
 Superficial veins 663  
 Orientation of the thumb 664

**Regional anatomy 665**

*Shoulder 665*

Bones 665  
 Joints 668  
 Muscles 675

*Posterior scapular region 678*

Muscles 678  
 Gateways to the posterior scapular region 680  
 Nerves 682  
 Arteries and veins 682

*Axilla 684*

Axillary inlet 685  
 Anterior wall 686  
 Medial wall 688  
 Lateral wall 690  
 Posterior wall 691  
 Gateways in the posterior wall 692  
 Floor 693  
 Contents of the axilla 693

**Arm 710**

Bones 712  
 Muscles 715  
 Arteries and veins 717  
 Nerves 720

**Elbow joint 724**

**Cubital fossa 729**

**Forearm 731**

Bones 732  
 Joints 734

**Anterior compartment of the forearm 736**

Muscles 736  
 Arteries and veins 742  
 Nerves 743

**Posterior compartment of the forearm 745**

Muscles 745  
 Arteries and veins 750  
 Nerves 751

**Hand 751**

Bones 752  
 Joints 754  
 Carpal tunnel and structures at the wrist 756  
 Palmar aponeurosis 758  
 Palmaris brevis 759  
 Anatomical snuffbox 759  
 Fibrous digital sheaths 759  
 Extensor hoods 760  
 Muscles 762  
 Arteries and veins 767  
 Nerves 770

**Surface anatomy 775**

Upper limb surface anatomy 775  
 Bony landmarks and muscles of the posterior scapular region 775  
 Visualizing the axilla and locating contents and related structures 777  
 Locating the brachial artery in the arm 779  
 The triceps brachii tendon and position of the radial nerve 779  
 Cubital fossa (anterior view) 779  
 Identifying tendons and locating major vessels and nerves in the distal forearm 781  
 Normal appearance of the hand 782  
 Position of the flexor retinaculum and the recurrent branch of the median nerve 783  
 Motor function of the median and ulnar nerves in the hand 783  
 Visualizing the positions of the superficial and deep palmar arches 784  
 Pulse points 784

**Clinical cases 786**

## 8

## Head and neck

### Conceptual overview 796

#### General description 796

Head 796

Neck 798

#### Functions 799

Protection 799

Contains upper parts of respiratory and digestive tracts 799

Communication 800

Positioning the head 800

Connects the upper and lower respiratory and digestive tracts 800

#### Component parts 800

Skull 800

Cervical vertebrae 802

Hyoid bone 803

Soft palate 804

Muscles 804

#### Relationship to other regions 805

Thorax 805

Upper limbs 805

#### Key features 806

Vertebral levels CIII/IV and CV/VI 806

Airway in the neck 806

Cranial nerves 807

Cervical nerves 808

Functional separation of the digestive and respiratory passages 808

Triangles of the neck 811

### Regional anatomy 812

#### Skull 812

Anterior view 812

Lateral view 814

Posterior view 816

Superior view 818

Inferior view 819

#### Cranial cavity 822

Roof 822

Floor 823

#### Meninges 830

Cranial dura mater 830

Arachnoid mater 833

Pia mater 833

Arrangement of meninges and spaces 834

#### Brain and its blood supply 835

Brain 835

Blood supply 837

Venous drainage 842

#### Cranial nerves 848

Olfactory nerve [I] 849

Optic nerve [II] 850

Oculomotor nerve [III] 850

Trochlear nerve [IV] 850

Trigeminal nerve [V] 851

Ophthalmic nerve [V<sub>1</sub>] 852

Maxillary nerve [V<sub>2</sub>] 852

Mandibular nerve [V<sub>3</sub>] 852

Abducent nerve [VI] 852

Facial nerve [VII] 852

Vestibulocochlear nerve [VIII] 853

Glossopharyngeal nerve [IX] 853

Vagus nerve [X] 853

Accessory nerve [XI] 854

Hypoglossal nerve [XII] 854

#### Face 856

Muscles 857

Parotid gland 863

Innervation 865

Vessels 869

#### Scalp 873

Layers 873

Innervation 874

Vessels 876

Lymphatic drainage 877

#### Orbit 878

Bony orbit 878

Eyelids 879

Lacrimal apparatus 882

Sensory innervation 882

Fissures and foramina 885

Fascial specializations 886

Muscles 887

Vessels 892

Innervation 893

Eyeball 898

#### Ear 902

External ear 903

Middle ear 906

Internal ear 913

#### Temporal and infratemporal fossae 920

Bony framework 920

Temporomandibular joints 922

Masseter muscle 925

Temporal fossa 926

Infratemporal fossa 929

#### Pterygopalatine fossa 940

Skeletal framework 940

Gateways 941

Contents 942

## **Neck 947**

- Fascia 948
- Superficial venous drainage 950
- Anterior triangle of the neck 954
- Posterior triangle of the neck 968
- Root of the neck 976

## **Pharynx 985**

- Skeletal framework 986
- Pharyngeal wall 987
- Fascia 990
- Gaps in the pharyngeal wall and structures passing through them 990
- Nasopharynx 991
- Oropharynx 993
- Laryngopharynx 993
- Tonsils 993
- Vessels 994
- Nerves 996

## **Larynx 997**

- Laryngeal cartilages 998
- Extrinsic ligaments 1000
- Intrinsic ligaments 1001
- Laryngeal joints 1002
- Cavity of the larynx 1003
- Intrinsic muscles 1005
- Function of the larynx 1008
- Vessels 1010
- Nerves 1012

## **Nasal cavities 1013**

- Lateral wall 1014
- Regions 1015
- Innervation and blood supply 1016
- Skeletal framework 1016
- External nose 1018
- Paranasal sinuses 1018
- Walls, floor, and roof 1020

- Nares 1024
- Choanae 1024
- Gateways 1024
- Vessels 1026
- Innervation 1028

## **Oral cavity 1030**

- Multiple nerves innervate the oral cavity 1031
- Skeletal framework 1031
- Walls: the cheeks 1034
- Floor 1035
- Tongue 1037
- Salivary glands 1044
- Roof—palate 1047
- Oral fissure and lips 1055
- Oropharyngeal isthmus 1055
- Teeth and gingivae 1056

## **Surface anatomy 1061**

- Head and neck surface anatomy 1061
- Anatomical position of the head and major landmarks 1062
- Visualizing structures at the CIII/CIV and CVI vertebral levels 1063
- How to outline the anterior and posterior triangles of the neck 1063
- How to locate the cricothyroid ligament 1064
- How to find the thyroid gland 1065
- Estimating the position of the middle meningeal artery 1066
- Major features of the face 1067
- The eye and lacrimal apparatus 1068
- External ear 1069
- Pulse points 1070

## **Clinical cases 1071**

Index **1081**

This page intentionally left blank